



PATIENT

Rylie Bourgeois

SPECIES

Canine

BREED

Chihuahua

SEX

Male Neutered

AGE

14 years

WEIGHT

12.2lbs

INTERPRETED BY

Maggie Machen
Lamy, DVM
DACVIM (Cardiology)

IMAGING PERFORMED BY

Eduardo Rodriguez
III, RCS

HOSPITAL NAME

Wignall Animal
Hospital

REFERRING VET

Dr. Dietrich

INVOICE

29550

DATE

3/30/23

PRESENTING CLINICAL SIGNS

History: Coughing, no murmur heard. Radiographs: Subjective cardiac enlargement, dorsal displacement of trachea - no apparent murmur, moderate tracheal collapse thoracic inlet. Current meds: 1)Hydrocodone Bitartrate Oral tablets: 5mg with Homatropine MBr 1.5 mg 1/4-1/2 tablet by mouth twice daily for cough. BP: 180, 181, 186mmHg.

ECHOCARDIOGRAM FINDINGS

2D, m-mode, color flow and Doppler imaging is available.

Left ventricle: The LV diameter is borderline increased with hyperdynamic function. LV wall thicknesses are normal.

Left atrium: The left atrium is moderately dilated.

Mitral valve: The mitral valve is diffusely thickened with marked prolapse into the left atrial lumen. Moderate to severe eccentric mitral regurgitation with a normal velocity.

Aortic valve/Aorta: The aortic valve is normal in morphology and mobility. Normal aortic outflow velocity; laminar flow. No aortic insufficiency.

Right ventricle: Normal right ventricular diameter and morphology indicating no overt evidence of pulmonary arterial hypertension.

Right atrium: Normal RA dimension.

Tricuspid valve: The tricuspid valve appears thickened with septal prolapse and mild tricuspid regurgitation. Normal velocity.

Pulmonic valve/Pulmonary artery: The pulmonic valve is normal in morphology and mobility. No pulmonic insufficiency. Normal RVOT velocity; laminar flow.

Pericardium/other: No pericardial or pleural effusion noted. No obvious cardiac masses.

Heart rhythm: ECG reveals a sinus rhythm with an average HR of 100bpm.

2-Dimensional Measurements

Ao diam (cm)	1.3
LA diam (cm)	2.2
LA:Ao (Swe)	1.7
IVS thickness (cm)	0.6
LVID diastole (cm)	2.5
PW thickness (cm)	0.6
LVID systole (cm)	1.4
FS (%)	45

Doppler Measurements

PV Vmax (m/s)	0.7
AoV Vmax (m/s)	1.3
MR Vmax (m/s)	5.5
TR Vmax (m/s)	2.5
TR PG (mmHg)	25

INTERPRETATION OF THE FINDINGS

Chronic degenerative valve disease causing moderate to severe mitral and mild tricuspid regurgitation. Moderate left atrial enlargement indicates there is relatively low risk for imminent complication, however risk for progression to spontaneous congestive heart failure in the future is elevated. No additional issues are identified.

Given LA dilation, Pimobendan is recommended as below. Assessment of progression in the future will help predict long term outcome, however prognosis is guarded at this stage (B2).

The cough is suspected to be due to a combination of mainstem bronchi compression and potentially airway disease in this predisposed breed. Continue Hydrocodone as needed.



PATIENT

Rylie Bourgeois

SPECIES

Canine

BREED

Chihuahua

SEX

Male Neutered

AGE

14 years

WEIGHT

12.2lbs

INTERPRETED BY

Maggie Machen
 Lamy, DVM
 DACVIM (Cardiology)

IMAGING PERFORMED BY

Eduardo Rodriguez
 III, RCS

HOSPITAL NAME

Wignall Animal
 Hospital

REFERRING VET

Dr. Dietrich

INVOICE

29550

DATE

3/30/23

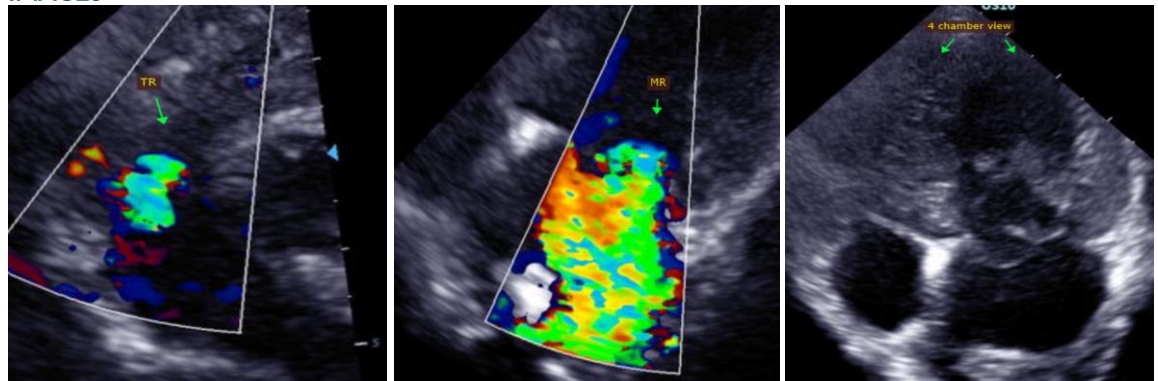
RECOMMENDATIONS

- Institute heart muscle support Pimobendan 0.3mg/kg PO q12h.
- Continue Hydrocodone as needed.
- Omega fatty acid supplementation and mild salt restriction may be of some long-term benefit.
- Once on Pimobendan for 3-5 days, anesthetic risk is considered mild if needed. Cardiac protective drug choices (opioid/benzodiazepine premedication, propofol or alfaxalone induction, isoflurane gas) are recommended. Pre-oxygenate for 5-10 minutes prior to induction. Monitor for arrhythmias, hypotension, and hypoxia both intra and post-operatively and intervene as necessary. Mild IV fluid restriction is recommended to avoid fluid overload. Avoid heart rate stimulating drugs such as atropine unless clinically indicated.
- Monitor for development of a cough, labored breathing, exercise intolerance or collapse episodes.

PLAN

- Recommend conservative monitoring with a recheck echocardiogram in 6 months, sooner if any development of clinical signs.

IMAGES



The information and recommendations provided are based on the images presented by the referring veterinarian. No evaluation can be communicated regarding pathology that was not visible in the image/video clips provided.

Thank you for this referral. This report was generated using transcription software, and minor dictation errors may be present. If the clinical or image interpretation does not parallel your findings or if I can be of any further assistance, please contact me.

Maggie Machen Lamy, DVM
 Diplomate of the American College of Veterinary Internal Medicine (Cardiology)
 info@sonopath.com

Echocardiogram performed by: Pamela Harrigan, RDCS
 Pet Animal Ultrasound Service (4paus.com)